

Original Article

Arthroscopic and Open Procedures Result in Similar Calcaneal Tunnels for Anatomical Reconstruction of Lateral Ankle Ligaments

Linxin Chen, M.D., Xin Xie, M.D., Peng Cao, M.D., Qinwei Guo, M.D., Dong Jiang, M.D., Chen Jiao, M.D., and Yanbin Pi, M.D., Ph.D.

Purpose: The purpose of this study was to validate the accuracy and reliability of arthroscopic markers of distal insertion of the calcaneofibular ligament (CFL), and to compare the calcaneus bone tunnels of the CFL that were made under arthroscopy and open procedures. **Method:** Fifty-seven patients who underwent lateral ankle ligament reconstruction procedures were enrolled and divided into open ($n = 24$) and arthroscopic groups ($n = 33$). Lateral ankle radiography was performed postoperatively, and the calcaneus bone tunnels referenced to several landmarks, including the subtalar joint, calcaneus superior edge, fibular tip, angulation with fibula axis, cross point of the fibular and tangential line of the fibular obscure tubercle cross point of the tangential lines of the talar posterior edge and deepest point of the subtalar joint, and cross point of the fibular axis and perpendicular line across fibular tip. These results were compared between the two groups. **Result:** No significant intergroup differences were observed between the parameters. When the bone tunnels of the CFL were referenced to the cross point of tangential lines of the talar posterior edge and deepest point of the subtalar joint, and the cross point of the fibular axis and perpendicular line across fibular tip, the coefficient variations were very high, which indicated that the locations of the bone tunnels were scattered over a large area in both groups. **Conclusion:** Arthroscopic and open procedures achieved similar results for calcaneus bone tunnel making of the CFL. However, large variations were observed in both groups.

Introduction

Ankle sprain is the most common injury and accounts for 10–30% of all sports medicine injuries.¹ According to previous studies, 40% of ankle sprains result in chronic ankle instability (CAI),² which is characterized by symptoms of repetitive sprain, chronic pain, and swelling. As the disorder progresses, 60% of cases may combine with osteochondral lesions

of talar (OLT) and develop into osteoarthritis and varus deformity of the ankle, which jeopardize sports activity and daily living of patients.^{3–6} For lateral ankle ligament injuries with persistent symptoms, failure of conservative treatment for at least 6–12 months, surgical intervention should be required.⁷

Numerous surgical procedures for the treatment of CAI have been reported with good clinical results.^{8,9} However, for those patients with poor ligament tissue quality, generalized hyperlaxity or collagen disorders, high body mass index (BMI), and high athletic-demand, lateral ligament reconstruction using autograft or allograft tendons was always required.^{10–12}

Compared to classical shortening or insertional repair of lateral ligaments, such as the Brostrom and Karlsson procedures,⁹ reconstruction procedures require more profound understanding of the anatomy of lateral ligament insertions to achieve optimal bone tunnels.^{11,12} Many studies have provided anatomic references for the distal insertion of the calcaneofibular ligament (CFL) for CFL reconstruction.^{13–15} According to those studies, several anatomical measurements were used to locate the calcaneal footprint of the CFL, but there was still a lack of consensus.^{14–17}

From the Institute of Sports Medicine, Peking University Third Hospital, Haidian District, Beijing, People's Republic of China (L.C., X.X., Q.G., D.J., C.J., Y.P.); Orthopedics Dept. 1, Cangzhou Hospital of Integrated TCM-WM, Cangzhou City, Hebei Province, People's Republic of China (P.C.).

The authors report no conflicts of interest in the authorship and publication of this article. Full ICMJE author disclosure forms are available for this article online, as supplementary material.

Received September 3, 2022; accepted March 29, 2023.

Address correspondence to Yanbin Pi, M.D., Ph.D., Institute of Sports Medicine, Peking University Third Hospital, 49 North Garden Road, Haidian District, Beijing, 100191, PR China. E-mail: piyb@vip.sina.com

© 2023 THE AUTHORS. Published by Elsevier Inc. on behalf of the Arthroscopy Association of North America. This is an open access article under the CC BY-NC-ND license (<http://creativecommons.org/licenses/by-nc-nd/4.0/>). 2666-061X/221164

<https://doi.org/10.1016/j.asmr.2023.03.010>

Compared to traditional open procedures, arthroscopic reconstruction procedures face different anatomical conditions and greater challenges in locating distal insertions of the CFL. The purposes of this study were to validate the accuracy and reliability of arthroscopic markers of distal insertion of the CFL and to compare the calcaneus bone tunnels of the CFL that were made under arthroscopy and open procedures. We hypothesized that both the arthroscopic and open procedures would achieve similar calcaneus bone tunnels of the CFL and that the markers would be accurate and reliable.

Materials and Methods

Protocol Approval

All the participants understood the purpose of this study and provided informed consent prior to participation according to the ethical standards of the Declaration of Helsinki, and this research was conducted with the approval of Peking University Third Hospital Medical Science Research Ethics Committee (No. M2021360). Patients treated with the reconstruction procedure were identified among 1,697 hospitalized surgical patients with CAI between 2018 and 2021. Between 2018 and 2019, open reconstruction procedures were performed by all of the surgeons. Between 2019 and 2021, arthroscopic procedures were performed by three of the surgeons (Q. W. Guo, C. Jiao, Y. B. Pi), while the others continued to perform open procedures. The inclusion criteria were as follows: patients with CAI with repetitive sprain or persistent symptoms of pain and swelling for at least 6 months, with failure of conservative treatment; and preoperative magnetic resonance imaging (MRI) and intraoperative investigation that revealed poor-quality ligament tissues that required a reconstruction procedure. The exclusion criteria were as follows: insertional repair of lateral ankle ligaments, only anterior talar-fibular ligament (ATFL) reconstruction procedure performed, interosseous talocalcaneal ligament combined with CFL reconstruction, varus or valgus deformity requiring osteotomy correction, infection involving ipsilateral ankles, neuromuscular injury requiring a tendon transfer procedure, and severe ankle fracture or dislocation requiring surgical intervention. All reconstruction procedures were performed by 6 surgeons (L.X. Chen, X. Xie, Q.W. Guo, D. Jiang, C. Jiao, Y.B. Pi) specializing in ankle and foot sports medicine at a single institution. The demographics for included patients were collected: age, sex, Beighton score, BMI, and duration from the first injury or symptom onset.

Surgical Techniques

For the arthroscopic procedure,^{11,16} after general or spinal anesthesia, patients were placed in the

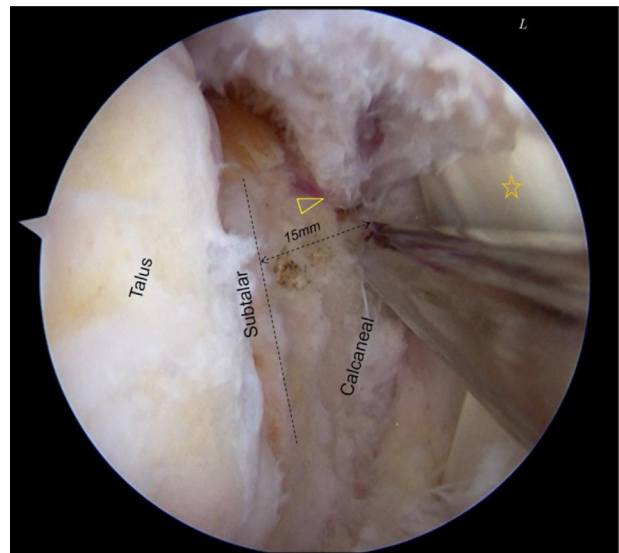


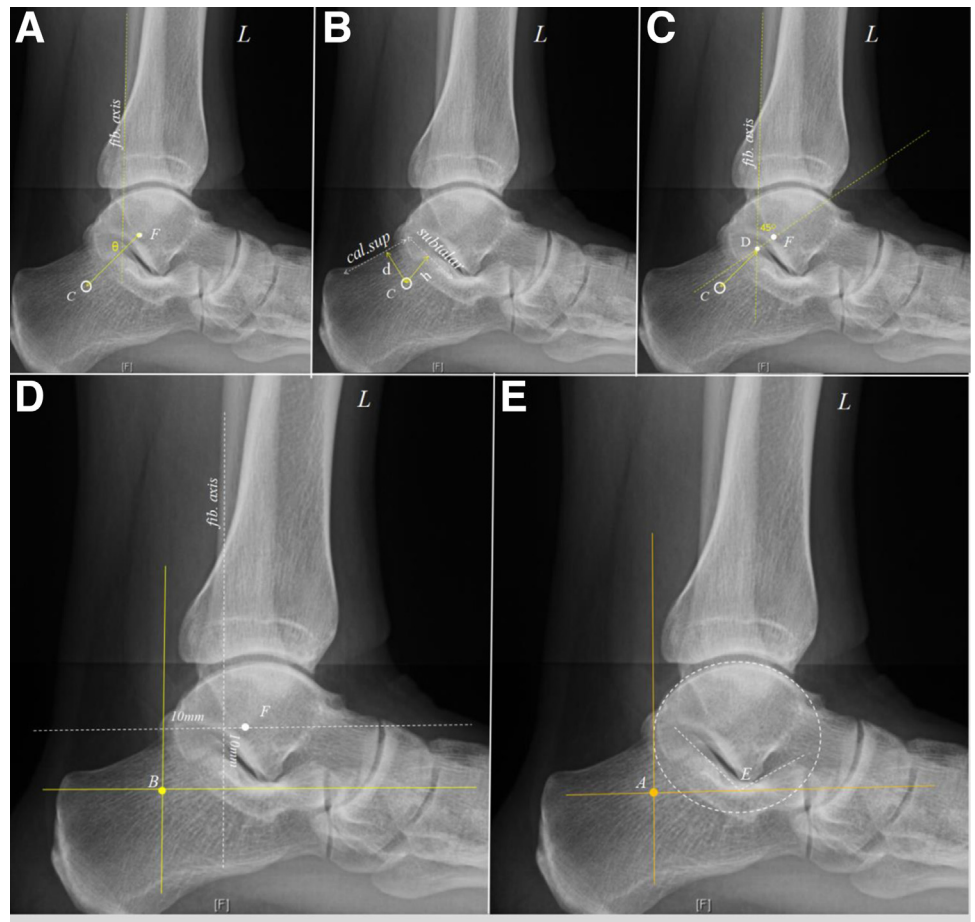
Fig 1. Arthroscopic view and location of the distal insertion of the calcaneofibular ligament (CFL). After releasing the capsule and scar tissues, the stump of the CFL was exposed, and a radio frequency head with a diameter of 4.0 mm was used to measure 15–20 mm below the subtalar joint. A metal trocar was located on the bony tunnel of the CFL. Open yellow triangle denotes CFL stump; open yellow star denotes peroneal tendon.

semilateral decubitus position, and a pneumatic thigh tourniquet was used to control the pressure at 300 mmHg. A longitudinal incision was made medial to the tibial tubercle. The gracilis tendon was harvested with a length of 16 cm, diameter of 4.5 mm, and folded in half into a “Y”-shape strand. The folded end was at least 20 mm long for fibular reconstruction, and the two free ends were prepared: 35 mm for ATFL and 45 mm for CFL reconstruction. The three ends of tendon were sutured 20 mm in length using 2# orthocords sutures (DePuy Synthes, Warsaw, IN).

Standard antero-lateral and antero-medial portals were constructed with ankle dorsiflexion. A 4.0-mm scope was introduced into the ankle joint, and the associated injuries, such as osteophytes and osteochondral lesions, free bodies, and synovitis were treated appropriately. The scar tissues, capsule, and the ATFL were derided and released by a shaver inserted via the AL portal. Then, the scope was transferred to the AL portal, and an accessory portal was made at the sinus tarsi for the shaver operation to expose the distal insertion of the CFL. References were used to arthroscopically locate the calcaneus insertion of the CFL: 5–10 mm distal to the peroneal tendon, 15–20 mm below the subtalar joint, and the remaining stump of the CFL (Fig 1).

A 5-mm bone tunnel was drilled at the fibular obscure tubercle (FOT), calcaneus insertion of the CFL, and talar insertion of the ATFL. The folded end of the

Fig 2. Anatomic parameters for the distal insertion of the calcaneofibular ligament (CFL). (A). Angle (θ) between the line of the CFL bone tunnel to the fibular tip and the line of the fibular longitudinal axis. (B) CFL to the subtalar joint (h) and CFL to the calcaneal superior edge (d). (C) CFL bone tunnel to the cross point (D) of the line of the fibular posterior cortex and the line that the 45° angle passed through the FOT. (D): CFL bone tunnel to the cross point (criteria B) of the line of the fibular posterior cortex and the perpendicular line through the fibular tip. (E): CFL bone tunnel to the cross point (criteria A) between the vertical line tangential to the posterior convexity of the talus and the perpendicular line tangential to the deepest concavity of the subtalar joint. *fib.axis*: the line of the fibular posterior cortex; *cal.sup*: calcaneal superior edge; *subtalar*: the mid point of the lateral border of the posterior facet of the subtalar joint. C, distal insertion of the CFL; F, fibular tip,



tendon was pulled into the fibular bone tunnels and fixed using a 4.50-mm footprint suture anchor (Smith & Nephew, Mansfield, MA). The free ends of the tendon were pulled into the talar and calcaneus bone tunnels, tensioned, and fixed using a 5.0 × 12 mm Milagro interference screw (Mitek, Norderstedt, Germany).

For the open procedure, A 12-cm-long curved incision was centered over the fibular tip and extended anteriorly over the lateral talus and posteriorly over the lateral calcaneus and posterior border of the fibula. The lateral ligament and capsule were dissected to expose the fibular, talus, and calcaneal insertion of the ligament. The following procedure and locating references of the bone tunnels were the same as for the arthroscopic procedure mentioned above.¹¹

Postoperative Radiological Evaluation

According to the measurements of previous studies,^{13,15,17-21} radiographic parameters were measured and compared on lateral ankle radiographs to determine the reliability and reproducibility of calcaneal bone tunnels in each group. For radiographic

viewing and measuring, we used the GE Centricity Enterprise Web 3 (GE Medical Systems) image system with magnification rate of 2.

The following parameters were measured (Fig 2): 1) CFL to the subtalar joint (h): CFL bone tunnel to the midpoint of the lateral border of the posterior facet of the subtalar joint¹⁹; 2) CFL to calcaneal superior edge (d): CFL bone tunnel to the superior edge of the calcaneal tubercle¹⁸; 3) CFL to fibular tip (C to F): CFL bone tunnel to the fibular tip¹⁵; 4) Angle with fibula (θ): Angle between the line from the CFL bone tunnel to the fibular tip and the line of fibula longitudinal axis²⁰; 5) CFL to the cross point of the fibular and tangential line of the FOT (D): the CFL bone tunnel to the cross point of the line of the fibular posterior cortex and the line of 45° angle passed through the antero-inferior part of the lateral malleolus (corresponding to the FOT)¹³; 6) CFL to the cross point (A) of the tangential lines of the talar posterior edge and deepest point of the subtalar joint: CFL bone tunnel to the cross point between the vertical line tangential to the posterior convexity of the talus and the perpendicular line tangential to the deepest concavity of the subtalar

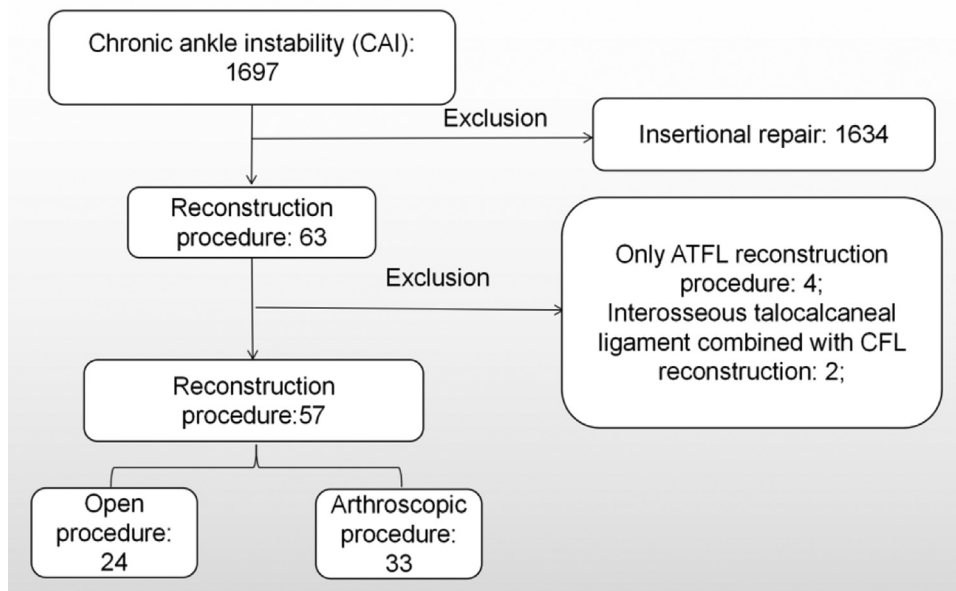


Fig 3. Enrollment flowchart.

joint¹⁷; and 7) CFL to the cross point (B) of the CFL bone tunnel to the cross point of the line 1 cm of the fibular posterior cortex and the perpendicular line 1 cm to the fibular tip.²¹

To evaluate the reliability and consistency of calcaneal bone tunnel-making more precisely, the calcaneus insertion of the CFL was assumed by two locating criteria, the Criteria A: the CFL bone tunnel to the cross point (A); Criteria B: CFL bone tunnel to the cross point B. Two lines referencing the corresponding bony markers were depicted as the *x*-axis and *y*-axis, and the distances from the bone tunnels to the *x*/*y*-axis and center point were measured and compared on a two-dimensional scale.

Statistical Analysis

The radiological locations of the calcaneus tunnel of the CFL were measured independently by two experienced surgeons (P.C. and Y.B.P.), and average values were adapted for the study to determine differences between the arthroscopic and open procedures. The patients' baseline characteristics and radiological measurements were analyzed and compared using a *t*-test. A *P* value <.05 was considered statistically significant. The reliability and consistency of bone tunnel making in the 2 groups were determined by the coefficient of variation (CV), which was calculated as the standard deviation divided by the mean value of each group. A CV of 0.2 was an important determinant of variability, <0.2 indicated a low degree of variability, and >0.2 indicated a high degree of variability. A lower value indicated higher reliability and consistency of the procedure used in the group. SPSS 19 software (IBM Corp, Armonk, NY) was used for statistical analysis.

Results

Fifty-seven patients underwent a reconstruction procedure for both the ATFL and CFL (Fig 3). The patients were divided into 2 groups: an open group (*n* = 24) and an arthroscopic group (*n* = 33). Moreover, no significant intergroup differences were seen regarding demographic features, including sex, age, BMI, Beighton score, and duration of injury (Table 1).

No significant differences were seen between several radiographic parameters. Several radiographic parameters were measured and compared on lateral ankle radiographs, including CFL to subtalar joint, CFL to calcaneal superior edge, CFL to fibular tip, angle with fibula, CFL to the cross point of the fibular and tangential line of the FOT, CFL to the cross point of the tangential lines of the talus and subtalar joint, CFL to the cross point of the fibular axis and perpendicular line across the fibula tip (Table 2).

The distances of CFL bone tunnel to the criteria A and B were measured, although the mean value of each distance was comparable and showed no statistically significant differences, the coefficient variations, especially in the *y*-axis of criterion A (bone tunnel reference to the deepest concavity of the subtalar joint), were high enough to prove that the location of the bone tunnels were scattered over a large area in the two groups (Fig 4, Table 3).

Discussion

In this study, we observed that both the arthroscopic and open procedures resulted in similar calcaneal bone tunnels of the CFL, but there were large variations in the location of the tunnels that were seen in both

Table 1. Demographic Features

	Group		P Value
	Arthroscopic	Open	
Number	33	24	N/A
Sex	Male, 24; Female, 9	Male, 20; Female, 4	.23
Age, year (Means \pm AD)	34.8 \pm 10.7	30.6 \pm 5.3	.13
BMI (Means \pm AD)	25.6 \pm 2.6	24.9 \pm 4.0	.68
Duration of injury (Week) (Means \pm AD)	35.5 \pm 30.9	36.9 \pm 40.2	.92
Beighton score (Means \pm AD)	4.0 \pm 1.5	3.8 \pm 1.4	.70

AD, average deviation; BMI, body mass index.

groups. Arthroscopic reconstruction of the lateral ankle ligament has been widely used to restore the stability of ankle joints in patients with poor ligament tissue quality, generalized hyperlaxity or collagen disorders, high BMI, or high athletic demand.¹⁰⁻¹² Compared to the traditional open procedure, the arthroscopic procedure demonstrated similarly good patient satisfaction as the open procedure, with less surgical incisions. However, more complications were observed in the arthroscopic procedure.²² This indicated that the high-level surgical skills required for the arthroscopic procedure were challenged, and there was room for technique improvement. One of the urgent problems to be solved is the identification of footprints for bone tunnel making, especially for the calcaneus footprint of the CFL, which required an operation outside the ankle joint and debridement deep below the peroneal tendon sheath. Moreover, previous anatomical studies reported distinct anatomical and morphological variants of the CFL.²³ Further, the calcaneus insertion of the CFL varied extensively. The CFL length varied substantially from 18.5 to 35.8 mm²⁴; the distances to the posterior aspect of the inferior peroneal retinaculum and subtalar joint ranged from 9 to 17 mm²⁴ and from 10 to 17 mm,²⁴ respectively, and the peroneal tubercle was located \sim 16–27 mm from the CFL insertion.^{14,25}

Consistent and reliable anatomical landmarks to locate the calcaneus insertion of CFL are lacking. Several parameters were applied to locate the calcaneus insertion of CFL. The angle between the ATFL and CFL was consistent, from 100° to 105°. ¹⁵ Additionally, the CFL formed a 133° (range: 113–150°) angle with the longitudinal axis of the fibula.²⁶ The peroneal tubercle was located \sim 16–27 mm antero-inferior to the CFL insertion and was believed to be a reproducible reference landmark for the distal insertion of the CFL.^{14,25} Another small tubercle (tuberculum ligament calcaneofibularis), which was believed to serve as a bony landmark for the calcaneal insertion of the CFL,¹⁷ was reported on the lateral surface of the calcaneus and posterior-superior to the posterior point of the peroneal process. It was easily palpated and located 1.6 mm (range: 0–4.1 mm) from the CFL insertion footprint centre. In Frederick Michels's measurements,¹³ the distal insertion of the CFL was located within a mean distance of 7.3 \pm 3.1 mm (1.2–12.4 mm) to the peroneal tendons. Additionally, the calcaneal insertion of the CFL was reportedly located 12.1–13 mm from the subtalar joint.²⁶⁻²⁸ Except for the measurements of the anatomical footprint of the CFL, Michels and Stockmans et al.¹³ discovered a new method to locate the ideal footprint of the CFL, which was based on two imaginary lines: the first was parallel to the long axis of the fibula and passed through the posterior point of the lateral malleolus. The second was at 45° to the first and passed through the antero-inferior part of the lateral malleolus, which corresponded to the obscure tubercle of the fibula. Another study²¹ provided a method to determine the optimal location of bone tunnels for a percutaneous technique. They drew a vertical line along the axis of the posterior diaphyseal fibular cortex, and another passing through the inferior tip of the lateral malleolus, where the distal insertion of the CFL was located 1 cm distally and 1 cm posterior from the cross point of the two lines. A similar method was reported by Brueggemann and colleagues.¹⁷ Two tangent lines were made from the deepest concavity of the

Table 2. Comparing the CFL Bone Tunnel to Anatomic References Between the Open and Arthroscopic Groups

CFL Bone Tunnel to the References	Open, mm	ICCs	Arthroscopy, mm	ICCs	P Value
Subtalar joint (means \pm SD)	18.4 \pm 3.4	0.76 (P < .001)	17.5 \pm 2.6	0.71 (P < .001)	>.05
Calcaneus superior edge (mean SD)	13.6 \pm 3.4	0.89 (P < .001)	14.4 \pm 4.5	0.95 (P < .001)	>.05
Fibular tip (means \pm SD)	21.9 \pm 4.3	0.89 (P < .001)	25.1 \pm 3.6	0.86 (P < .001)	>.05
Angle with fibula (means \pm SD)	131.4 \pm 17.7	0.88 (P < .001)	132.6 \pm 13.7	0.83 (P < .001)	>.05
The cross point of fibular and tangential line of FOT (means \pm SD)	12.8 \pm 3.9	0.86 (P < .001)	12.2 \pm 7.0	0.97 (P < .001)	>.05
The cross point of tangential lines of talus and subtalar joint (means \pm SD)	5.6 \pm 2.7	0.67 (P = .006)	6.8 \pm 3.7	0.86 (P < .001)	>.05
The cross point of the fibular longitudinal axis and perpendicular line across fibular tip (means \pm SD)	17.0 \pm 3.6	0.86 (P < .001)	19.1 \pm 3.5	0.79 (P < .001)	>.05

CFL, calcaneofibular ligament; ICC, intraclass correlation coefficient; SD, standard deviation.

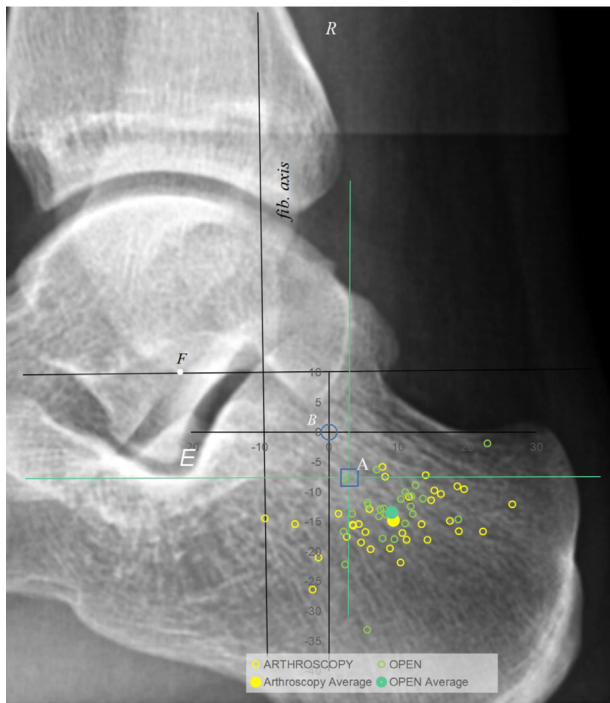


Fig 4. Calcaneus bone tunnel referenced to criteria A (open blue square) and B (open blue circle). Open yellow circle denotes bone tunnels in arthroscopic group, while the solid yellow circle denotes average value of bone tunnels in arthroscopic group. Open green circle denotes bone tunnels in open group, while solid green circle denotes average value of bone tunnels in open group. *fib.axis*, the line of the fibular posterior cortex, C, distal insertion of calcaneofibular ligament; E, the deepest concavity of subtalar joint, F, fibular tip.

tarsal sinus and posterior margin of the talus. They believed that a 6-mm diameter zone around the intersection most frequently depicted the distally marked CFL insertion. By drawing two crossed reference lines, the bone tunnels of the CFL could be located precisely and consistently. These methods can be used for intraoperative localization and postoperative valuation.

To date, the remnant of the CFL stump and 10–17 mm below the subtalar joint were the only arthroscopically detectable landmarks, and they were adapted as the main references to locate the calcaneus bone

tunnel of the CFL in arthroscopic and open procedures.²⁹⁻³²

In this study, the distances from the calcaneus bone tunnel to the different anatomical references were measured and compared between open and arthroscopic procedures. We found no statistical differences in radiographic parameters between the two groups. Either open or arthroscopic procedures can achieve similarly favorable results for calcaneus bone tunnel making of the CFL. This result may also be due to the large variation of radiographic parameters and the small sample size.

The calcaneus bone tunnels referenced two cross-point landmarks: the cross point of the vertical line tangential to the posterior convexity of the talus and the perpendicular line tangential to the deepest concavity of the subtalar joint (criteria A), and the cross point of the line 1 cm to the fibular posterior cortex and the perpendicular line 1 cm to the fibular tip (criteria B). Although the distances from the bone tunnel to criteria A and B demonstrated no significant differences between the two procedures, the coefficient of variations were large enough to reveal existing defects for this locating method. Aside from the anatomical variation of the calcaneus insertion of the CFL, reliance on one reference was not reliable to determine the location of the bone tunnel accurately and consistently. Another reference line, which could be visualized arthroscopically, should be drawn, and a cross point constructed with the reference line 10 to 17 mm below the subtalar joint. On the basis of this cross-locating method, we located the bone tunnel position more accurately and consistently. Moreover, large anatomical variation existed for the calcaneus footprint of the CFL; however, few studies have been able to confirm that the anatomical footprint is the most optimal location of the bone tunnel. Further biomechanical and anatomical research is required to clarify this point.

Limitations

The present study has a retrospective design. In addition, because different surgeons performed ligament reconstruction surgery in arthroscopic and open

Table 3. Comparing the CFL Bone Tunnel to the Criteria A and B Between the Open and Arthroscopic Groups.

		Arthroscopy			Open			P Value
		Means ± AD	SD	CV	Means ± AD	SD	CV	
To the cross point of tangential lines of talus and subtalar joint	Center	6.8 ± 3.7	5.2	0.8	5.6 ± 2.7	3.3	0.6	.30
	x-axis	3.0 ± 4.5	6.1	2.0	2.2 ± 3.7	4.6	2.1	.58
	y-axis	0.8 ± 4.3	5.2	6.9	0.4 ± 3.2	4.2	10.7	.77
The cross point of the fibular longitudinal axis and perpendicular line across fibular tip	Center	19.1 ± 3.4	4.5	0.2	17.1 ± 3.6	5.1	0.3	.85
	x-axis	9.3 ± 6.4	8.0	0.9	9.1 ± 3.8	5.0	0.8	.89
	y-axis	14.8 ± 3.6	4.6	0.3	13.7 ± 3.5	5.9	0.6	.36

AD, average deviation, CFL, calcaneofibular ligament; CV, coefficient of variation; SD, standard deviation.

groups, this may contribute to the variation of calcaneus bone tunnel making.

This study is not without limitations. One limitation is our sample size was small; therefore, the statistical power was not very large (0.4643), but this result has some reliability and guiding significance, and further research is needed.

The present study only compared the location of the bone tunnels on the calcaneus insertion between open and arthroscopic procedures. Without clinical outcome comparisons, we could not clarify the differences in clinical effects between open and arthroscopic procedures. Further, determining how the differences in bone tunnel location affected clinical outcomes was challenging. We proposed that a large variation exists in this bone tunnel-locating method; however, we do not provide and verify feasible solutions.

Conclusions

Arthroscopic and open procedures achieved similar results for calcaneus bone tunnel making of the CFL. However, large variations were observed in both groups.

Acknowledgment

This study is funded by the Clinical Cohort Construction Program of Peking University Third Hospital (No. BYSYDL2021021).

References

1. Fong DT, Hong Y, Chan LK, Yung PS, Chan KM. A systematic review on ankle injury and ankle sprain in sports. *Sports Med* 2007;37:73-94.
2. Gerber JP, Williams GN, Scoville CR, Arciero RA, Taylor DC. Persistent disability associated with ankle sprains: A prospective examination of an athletic population. *Foot Ankle Int* 1998;19:653-660.
3. Woods C, Hawkins R, Hulse M, Hodson A. The Football Association Medical Research Programme: An audit of injuries in professional football: An analysis of ankle sprains. *Br J Sports Med* 2003;37:233-238.
4. Hintermann B, Boss A, Schafer D. Arthroscopic findings in patients with chronic ankle instability. *Am J Sports Med* 2002;30:402-409.
5. Okuda R, Kinoshita M, Morikawa J, Yasuda T, Abe M. Arthroscopic findings in chronic lateral ankle instability: Do focal chondral lesions influence the results of ligament reconstruction? *Am J Sports Med* 2005;33:35-42.
6. Sammarco VJ. Complications of lateral ankle ligament reconstruction. *Clin Orthop Relat Res* 2001;391:123-132.
7. Allen T, Kelly M. Modern open and minimally invasive stabilization of chronic lateral ankle instability. *Foot Ankle Clin* 2021;26:87-101.
8. Vega J, Malagelada F, Dalmau-Pastor M. Ankle micro-instability: Arthroscopic findings reveal four types of lesion to the anterior talofibular ligament's superior fascicle. *Knee Surg Sports Traumatol Arthrosc* 2021;29:1294-1303.
9. Hamilton WG, Thompson FM, Snow SW. The modified Brostrom procedure for lateral ankle instability. *Foot Ankle* 1993;14:1-7.
10. Vila-Rico J, Cabestany-Castella JM, Cabestany-Perich B, Nunez-Samper C, Ojeda-Thies C. All-inside arthroscopic allograft reconstruction of the anterior talo-fibular ligament using an accessory transfibular portal. *Foot Ankle Surg* 2019;25:24-30.
11. Jung HG, Kim TH, Park JY, Bae EJ. Anatomic reconstruction of the anterior talofibular and calcaneofibular ligaments using a semitendinosus tendon allograft and interference screws. *Knee Surg Sports Traumatol Arthrosc* 2012;20:1432-1437.
12. Li H, Hua Y, Li H, Chen S. Anatomical reconstruction produced similarly favorable outcomes as repair procedures for the treatment of chronic lateral ankle instability at long-term follow-up. *Knee Surg Sports Traumatol Arthrosc* 2020;28:3324-3329.
13. Michels F, Matricali G, Wastyn H, Vereecke E, Stockmans F. A calcaneal tunnel for CFL reconstruction should be directed to the posterior inferior medial edge of the calcaneal tuberosity. *Knee Surg Sports Traumatol Arthrosc* 2020;29:1325-1331.
14. Neuschwander TB, Indresano AA, Hughes TH, Smith BW. Footprint of the lateral ligament complex of the ankle. *Foot Ankle Int* 2013;34:582-586.
15. Yang H, Su M, Chen Z, et al. Anatomic measurement and variability analysis of the anterior talofibular ligament and calcaneofibular ligament of the ankle. *Orthop J Sports Med* 2021;9:23259671211047269.
16. Guillo S, Cordier G, Sonnery-Cottet B, Bauer T. Anatomical reconstruction of the anterior talofibular and calcaneofibular ligaments with an all-arthroscopic surgical technique. *Orthop Traumatol Surg Res* 2014;100:S413-S417 (8 Suppl).
17. Best R, Mauch F, Fischer KM, Rueth J, Brueggemann GP. Radiographic monitoring of the distal insertion of the calcaneofibular ligament in anatomical reconstructions of ankle instabilities: A preliminary cadaveric study. *Foot Ankle Surg* 2015;21:245-249.
18. Haytmanek CT, Williams BT, James EW, et al. Radiographic identification of the primary lateral ankle structures. *Am J Sports Med* 2015;43:79-87.
19. Matsui K, Oliva XM, Takao M, et al. Bony landmarks available for minimally invasive lateral ankle stabilization surgery: A cadaveric anatomical study. *Knee Surg Sports Traumatol Arthrosc* 2017;25:1916-1924.
20. Yildiz S, Yalcin B. The anterior talofibular and calcaneofibular ligaments: An anatomic study. *Surg Radiol Anat* 2013;35:511-516.
21. Lopes R, Noailles T, Brulefert K, Geffroy L, Decante C. Anatomic validation of the lateral malleolus as a cutaneous marker for the distal insertion of the calcaneofibular ligament. *Knee Surg Sports Traumatol Arthrosc* 2018;26:869-874.
22. Guelfi M, Zamperetti M, Pantalone A, et al. Open and arthroscopic lateral ligament repair for treatment of chronic ankle instability: A systematic review. *Foot Ankle Surg* 2018;24:11-18.
23. Pereira BS, van Dijk CN, Andrade R, et al. The calcaneofibular ligament has distinct anatomic morphological variants: An anatomical cadaveric study. *Knee Surg Sports Traumatol Arthrosc* 2020;28:40-47.

24. Matsui K, Takao M, Tochigi Y, Ozeki S, Glazebrook M. Anatomy of anterior talofibular ligament and calcaneofibular ligament for minimally invasive surgery: A systematic review. *Knee Surg Sports Traumatol Arthrosc* 2017;25:1892-1902.
25. Clanton TO, Campbell KJ, Wilson KJ, et al. Qualitative and quantitative anatomic investigation of the lateral ankle ligaments for surgical reconstruction procedures. *J Bone Joint Surg Am* 2014;96:e98.
26. Burks RT, Morgan J. Anatomy of the lateral ankle ligaments. *Am J Sports Med* 1994;22:72-77.
27. Muzaffer SS. Anatomy of the lateral ankle ligaments. *Tr J Med Sci* 1998;28:53-56.
28. GTEB RB. Reconstruction of the lateral ligaments of the ankle: An anatomic study with evaluation of isometry. *J Sports Traumatol. rel. res* 1993;15:55-74.
29. Jung H, Kim T, Park J, Bae E. Anatomic reconstruction of the anterior talofibular and calcaneofibular ligaments using a semitendinosus tendon allograft and interference screws. *Knee Surg Sports Traumatol Arthrosc* 2012;20:1432-1437.
30. Matsui K, Oliva XM, Takao M, et al. Bony landmarks available for minimally invasive lateral ankle stabilization surgery: A cadaveric anatomical study. *Knee Surgery, Sports Traumatol Arthrosc* 2017;25:1916-1924.
31. Acevedo JL, Palmer RC, Mangone PG. Arthroscopic treatment of ankle instability. *Foot Ankle Clin* 2018;23:555-570.
32. Michels F, Cordier G, Burssens A, Vereecke E, Guillo S. Endoscopic reconstruction of CFL and the ATFL with a gracilis graft: A cadaveric study. *Knee Surg Sports Traumatol Arthrosc* 2016;24:1007-1014.