

## Original Article

# Transcoracoid Drilling for Coracoclavicular Ligament Reconstructions in Patients With Acromioclavicular Joint Dislocations Result in Eccentric Tunnels

Erik Hohmann, M.B.B.S., F.R.C.S., F.R.C.S. (Tr.&Orth.), Ph.D., M.D.,  
Sinmiloluwa Oduoye, B.Sc. Medical Sciences (UP),

Jolandie Myburgh, B.Sc. Medical Sciences (UP), B.Sc. Hons Physical Anthropology (UP),  
M.Sc. Anatomy (UP), Ph.D. Anatomy (UP),

Reinette van Zyl, B.Sc. Medical Sciences (UP), B.Sc. Hons Macro-Anatomy (UP),  
M.Sc. Anatomy (UP), and

Natalie Keough, B.Sc. Physiology (UP), B.Sc. Hons Physical Anthropology (UP),  
M.Sc. Anatomy (UP), Ph.D. Anatomy (UP)

**Purpose:** To determine the location of coracoid inferior tunnel exit with superior-based tunnel drilling and coracoid superior tunnel exit with inferior-based tunnel drilling. **Methods:** Fifty-two cadaveric embalmed shoulders (mean age 79 years, range 58-96 years) were used. A transcoracoid tunnel was drilled at the center of the base. Twenty-six shoulders were used for the superior-to-inferior tunnel drilling approach and 26 shoulders for the inferior-to-superior tunnel drilling approach. The distances to the margins of the coracoid process, from both the entry and exit points of the tunnel, were measured. Paired Student *t*-tests were used to compare the distance from the center of the tunnel and the medial and lateral coracoid border and the apex. **Results:** The mean difference for the distances between superior entry and inferior exit from the apex was  $3.65 \pm 3.51$  mm ( $P = .002$ );  $1.57 \pm 2.27$  mm for the lateral border ( $P = .40$ ) and  $5.53 \pm 3.45$  mm for the medial border ( $P = .001$ ). The mean difference for the distances between inferior entry and superior exit from the apex was  $16.95 \pm 3.11$  mm ( $P = .0001$ );  $6.51 \pm 3.2$  mm for the lateral border ( $P = .40$ ) and  $1.03 \pm 2.32$  mm for the medial border ( $P = .045$ ). Inferior-to-superior drilling resulted in 4 (15%) cortical breaks. **Conclusions:** Both superior-to-inferior and inferior-to-superior tunnel drilling directed the tunnel from a more anterior and medial entry to a posterior-lateral exit. Superior-to-inferior drilling resulted in a more posteriorly angled tunnel. When using a 5-mm reamer and inferior-to-superior tunnel drilling, cortical breaks were observed at the inferior and medial margin of the tunnel exit. **Clinical Relevance:** Arthroscopic-assisted acromioclavicular joint reconstruction using conventional jigs may result in an eccentric coracoid tunnel, possibly introducing stress risers and fractures. To avoid cortical breaks and eccentric tunnel placement, open drilling from superior-to-inferior with a superiorly centered guide pin and arthroscopic visualization of a centered inferior exit should be considered.

The incidence of acromioclavicular joint dislocations ranges from 1.8 to 2.0 per 100,000 population.<sup>1,2</sup> The most common mechanism of injury is traumatic

and typically is caused by involvement in sports.<sup>2</sup> Type III-VI injuries involve complete tears of the coracoclavicular (CC) ligament complex and are

From the Burjeel Hospital for Advanced Surgery, Dubai, United Arab Emirates (E.H.); School of Medicine, University of Pretoria, South Africa (E.H.); Department of Anatomy School of Medicine, Faculty of Health Sciences, University of Pretoria, South Africa (S.O., J.M., R.v.Z.); Department of Anatomy and Cellular Biology, College of Medicine & Health Sciences, Khalifa University, Abu Dhabi, United Arab Emirates (N.K.); and Department of Anatomy, University of Pretoria, Pretoria, South Africa (N.K.).

The authors report that they have no conflicts of interest in the authorship and publication of this article. Full ICMJE author disclosure forms are available for this article online, as [supplementary material](#).

Received October 11, 2022; accepted January 31, 2023.

Address correspondence to Erik Hohmann, M.B.B.S., F.R.C.S., F.R.C.S. (Tr.&Orth.), Ph.D., M.D., School of Medicine, Faculty of Health Sciences, University of Pretoria, Cnr Bophelo and Dr Savage Road, Gezina, Pretoria, 0001, South Africa. E-mail: [drerik@burjeelspecialty.com](mailto:drerik@burjeelspecialty.com)

© 2023 THE AUTHORS. Published by Elsevier Inc. on behalf of the Arthroscopy Association of North America. This is an open access article under the CC BY-NC-ND license (<http://creativecommons.org/licenses/by-nc-nd/4.0/>).  
2666-061X/221321

<https://doi.org/10.1016/j.asmr.2023.01.019>

characterized by 100% displacement of the clavicle in various planes.<sup>3</sup> Disruptions of these ligaments commonly cause both vertical and horizontal instability.<sup>3</sup> The CC ligament complex originates on the superior aspect of the coracoid base and inserts on the undersurface of the clavicle.<sup>4</sup> Although the management of type III dislocations remains controversial, surgical reconstruction should be considered in younger and functionally greater-demand patients.<sup>5</sup> Type IV-VI injuries generally are caused by high-energy trauma and are treated operatively.<sup>6</sup>

Several surgical techniques have been described and range from transclavicular screw fixation to arthroscopic-assisted techniques using transclavicular and transcoracoid tunnel drilling with button fixation.<sup>6</sup> Anatomic coracoid tunnel drilling placing the tunnel entry at the superior coracoid center of the CC ligament complex footprint results in cortical breaching in more than 90% of patients.<sup>7,8</sup> In contrast, coracoid tunnel placement by centering the tunnel on the superior and inferior coracoid process in a virtual model maintains adequate bony bridges and cortical margins.<sup>7</sup> However, transclavicular–transcoracoid tunnel drilling cannot restore the footprint of the CC ligament complex and is associated with a significant risk of cortical breach and fracture.<sup>9</sup> Not surprisingly, coracoid fractures have been reported to occur in up to 20%, with anatomic reconstructions of the CC ligaments.<sup>10,11</sup> In addition, the anatomic variability of the coracoid process varies widely and also needs to be considered to improve safety and reduce complications of CC ligament reconstruction.<sup>12</sup>

The purpose of this laboratory study was to determine the location of coracoid inferior tunnel exit with superior-based tunnel drilling and the coracoid superior tunnel exit with inferior-based tunnel drilling. It was hypothesized that both inferior- and superior-based drilling techniques would result in eccentric tunnel placements.

## Methods

Twenty-six pairs of adult human embalmed cadavers were obtained from the Department of Anatomy at the University of Pretoria, South Africa. These specimens were used during the anatomy courses for medical and health science students that were offered by the department during the 2019/2020 academic year. These cadavers are used for training purposes and comply with all the requirements set out in the National Health Act 62 of 2003. The embalmed specimens were used for the quantitative aspect of the study determining tunnel exit locations. This study was approved by the Faculty of Health Sciences Research Ethics Committee of the University of Pretoria, South Africa. Cadavers were excluded if they showed any macroscopic signs of fracture, or damage to the scapula, particularly the coracoid process. The embalmed

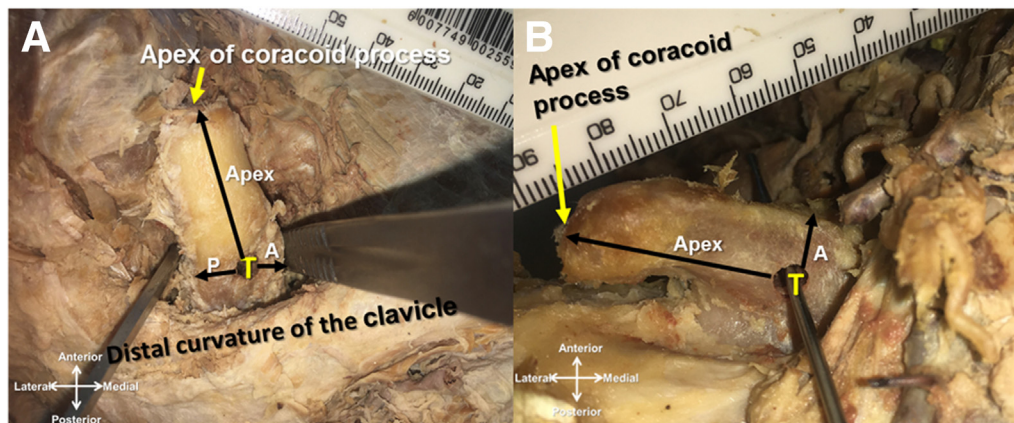
specimens consisted of 15 males and 11 females (mean age 79 years, range 58-96 years, 1 Black and 25 White cadavers).

## Coracoid Tunnel Drilling

Full-body size cadavers were placed supine on a dissection table, and 2 wooden bone blocks were positioned under both scapulae, resulting in slight elevation of the chest. The skin was removed from the posterior aspect of the trapezius muscle to the nipple.

The superior-to-inferior tunnel drilling was selected to reproduce open/mini-open acromioclavicular reconstructions with double-buttons with no obvious checks on inferior tunnel exit. For the superior approach, the pectoralis was dissected anterior to the clavicle until the coracoid was fully exposed along its entire length together with the superior, medial, lateral, and inferior surfaces (Fig 1). Two dissecting forceps were then placed at the medial and lateral edges of the coracoid base. The center of the superior base was established by measuring the distance between the two forceps and dividing the measured distance by two. The halfway point was marked and a 2-mm guide pin was used to establish the initial entry. A 5-mm cannulated drill bit was then used to complete tunnel drilling. A goniometer was used to ensure perpendicular entry for both anterior–posterior and medial–lateral planes. The distance from the tunnel entry to the apex and medial and lateral margins was measured with a digital caliper. The distance from the inferior tunnel exit to the apex and lateral and medial margins also was measured with a digital caliper. Tunnels were considered to be centered if the lateral and medial coracoid cortex was similar at both tunnel entry and tunnel exit.

The inferior-to-superior tunnel drilling was selected as a proxy to simulate arthroscopic-assisted CC tunnel drilling using a standard jig. With this technique, the jig is placed at the inferior aspect of the coracoid and centered guide pin placement is usually checked visually. With this standard technique, the guide pin and therefore superior tunnel entry cannot be controlled. For the inferior approach the arm was abducted to 90° so that the inferior coracoid base could be visualized. Similar to the superior approach, 2 dissecting forceps were then placed at the medial and lateral edges of the coracoid base and the steps described above were used to establish the coracoid tunnel. For easier drilling, a longer 5-mm cannulated drill bit was used and it is recognized that the longer lever arm could have possibly resulted in eccentric drilling movements at the inferior coracoid base. Again, the distance from the tunnel entry to the apex and medial and lateral margins was measured with a digital caliper, as was the distance from the superior tunnel exit to the apex and lateral and medial margins. To test for reliability, an independent research associate performed all measures 3



**Fig 1.** Right shoulder from caudal: (A) For the superior approach, the shoulder was dissected anterior to the clavicle until the coracoid was exposed along its entire length together with the superior, medial and lateral surfaces. A 2-mm guide pin bit was used to establish the initial entry and drilling was completed by a 5-mm cannulated drill bit. (B) For the inferior approach, the shoulder was abducted to 90 so that the inferior coracoid base could be visualized. Similar to the superior approach, the tunnel was predrilled with a 2-mm guide pin followed by a 5-mm cannulated drill bit to complete the tunnel. (T, coracoid tunnel position; A, distance from lateral border of the coracoid tunnel to the lateral border of the coracoid process; P, distance from the medial border of the coracoid tunnel to the medial border of the coracoid process.).

times, and these were then averaged. If there were any obvious outliers or any of the measures deviated by more than 5 mm, the outlier was excluded and the measurements were repeated.

### Statistical Analysis

Descriptive statistics were applied to describe measures of central tendency and variance. Paired student *t*-tests were used to compare the distance from the center of the tunnel and the medial and lateral coracoid border and the apex. IBM SPSS Statistics for Windows, version 21 (IBM Corp., Armonk, NY), was used to perform the data analysis.

## Results

### Superior Coracoid Entry–Inferior Coracoid Exit

The results for superior entry tunnel drilling and inferior tunnel exit measures are summarized in [Table 1](#). The coracoid width at the center of the tunnel was  $14.91 \pm 3.82$  mm. The mean difference for the distances between superior entry and inferior exit from the apex was  $3.65 \pm 3.51$  mm and was statistically significant ( $P = .002$ ). The 95% confidence intervals demonstrated minimal overlap, suggesting that these findings were relevant. The inferior exit was located closer to the coracoid base, indicating that the tunnels were angled posteriorly. The mean difference for the distances between superior entry and inferior exit from the medial border of the coracoid was  $5.53 \pm 3.45$  mm and was statistically significant ( $P = .001$ ). However, the 95% confidence intervals overlapped suggesting that these differences, although significant, were not relevant. The mean difference for the distances

between superior entry and inferior exit from the lateral border of the coracoid was  $1.57 \pm 2.27$  mm and was not statistically significant ( $P = .40$ ). Again, the 95% confidence intervals overlapped, suggesting that these differences were not relevant. The inferior exit was located slightly lateral, indicating that the tunnels were angled laterally. Tunnel drilling from superior to inferior therefore resulted in directing the inferior tunnel exit more posterior and slightly lateral. Cortical breaks were not observed with this technique.

### Inferior Coracoid Entry–Superior Coracoid Exit

The results for inferior entry tunnel drilling and superior tunnel exit measures are summarized in [Table 2](#). The coracoid width at the center of the tunnel was  $16.95 \pm 3.11$  mm. The mean difference for the distances between superior entry and inferior exit from the apex was  $6.05 \pm 2.56$  mm and was statistically significant ( $P = .0001$ ). The 95% confidence intervals overlapped, suggesting again that, although significant, these findings were not relevant. The superior exit was located closer to the coracoid base, indicating that the tunnels were angled posteriorly. The mean difference for the distances between inferior entry and superior exit from the medial border of the coracoid was  $-1.03 \pm 2.32$  mm and was statistically significant ( $P = .045$ ). The 95% confidence intervals did not overlap, suggesting that these differences were relevant despite the small mean differences. The mean difference for the distances between superior entry and inferior exit from the lateral border of the coracoid was  $6.51 \pm 3.20$  mm and was statistically significant ( $P = .0001$ ). The 95% confidence intervals again overlapped, suggesting that these differences were not relevant. Also, with this approach, it was more difficult

**Table 1.** Superior Entry–Inferior Exit

	Mean	SD	Range	95% CI	P Value
Superior entry					
Apex distance	26.11	5.02	14.3-26.5	24.18-28.04	
Medial distance	7.43	2.06	3.6-7.1	6.64-8.22	
Lateral distance	7.48	2.5	3.6-7.0	6.52-8.8	
Inferior exit					
Apex distance	22.52	6.3	11.3-23.2	20.1-24.94	
Medial distance	7.96	2.3	3.6-8.4	7.07-8.85	
Lateral distance	1.95	2.33	3.14-5.23	0.24-3.66	
Coracoid width	14.91	3.82	8.74-23.58	13.44-16.36	
Difference apex	3.65	3.51	0.41-11.35	2.25-5.05	.02
Difference medial	1.57	2.27	0.65-4.04	1.5-3.36	.40
Difference lateral	5.53	3.45	2.74-11.64	3.1-7.94	.001

CI, confidence interval; SD, standard deviation.

**Table 2.** Inferior Entry–Superior Exit

	Mean	SD	Range	95% CI	P Value
Inferior entry					
Apex distance	21.67	4.03	15.53-28.16	20.12-23.22	
Medial distance	7.00	1.66	4.8-10.72	6.36-7.64	
Lateral distance	6.94	1.65	4.7-9.09	6.24-4.64	
Superior exit					
Apex distance	27.47	4.85	20.28-39.7	25.61-29.33	
Medial distance	8.03	1.63	5.35-10.4	7.4-8.66	
Lateral distance	2.91	1.66	0.81-5.05	2.21-3.61	
Coracoid width	16.95	3.11	11.69-22.8	15.72-18.12	
Difference apex	6.05	2.56	2.75-13.95	5.43-6.67	.001
Difference medial	1.03	2.32	0.51-3.8	0.92-2.14	.045
Difference lateral	6.51	3.20	2.49-10.98	4.27-8.75	.001

CI, confidence interval; SD, standard deviation.

to consistently drill tunnels, and the wider range for these differences indicates that inferior-to-superior tunnel drilling is less reliable. The superior exit was located slightly lateral, indicating that the tunnels were angled laterally. Similar to superior–inferior drilling inferior to superior resulted in directing the superior tunnel exit more posterior and slightly lateral. Four cortical breaks were observed with this technique and occurred at the medial margin of the tunnel exit. All cortical breaks were observed on female specimens with a hooked-shaped coracoid process.

## Discussion

The most important findings of this study were that both superior-to-inferior and inferior-to-superior tunnel drilling directed the tunnel from a more anterior and medial entry to a posterior–lateral exit. The superior-to-inferior drilling resulted in a more posteriorly angled tunnel. With inferior-to-superior tunnel drilling, cortical breaks were observed at the inferior and medial margin of the tunnel.

Arthroscopic acromioclavicular joint reconstruction using a double-button technique is now commonly employed and has demonstrated good clinical outcomes.<sup>13,14</sup> This technique relies on a CC guide that is centered on the inferior surface of the coracoid base and on the superior surface of the clavicle.<sup>15</sup> A guide pin is then drilled from the clavicle into the coracoid and over reamed with a cannulated drill bit.<sup>15</sup> This technique is based on the assumption that by centering the inferior tunnel exit results in a centered superior coracoid tunnel entry. Unfortunately, the morphology of the coracoid varies substantially, is not of a typical rectangular shape, and is not positioned parallel to the clavicle, thereby reducing the likelihood of a centered coracoid tunnel. Koh et al.<sup>8</sup> have shown in a cadaveric study that anatomic tunnel placement is not feasible with transclavicular–transcoracoid drilling and can result in medial cortical breaches in 50% with an eccentric and medially displaced tunnel exit. For this

study, arthroscopic transcoracoid tunnel drilling was simulated by establishing the center of the inferior coracoid base and performing tunnel drilling from inferior to superior. The superior tunnel exit was located more lateral, indicating an angled coracoid tunnel from medial to lateral, which corresponds to a more lateral tunnel entry on the superior coracoid when using a superior–inferior transclavicular–transcoracoid drilling technique. Cortical breaches were observed on the medial margin of the tunnel exit in 15% of the sample. These findings confirm the results of Koh et al.<sup>8</sup> that the medial coracoid cortex is at risk of cortical breaks. All cortical breaks occurred in hooked-shaped coracoid processes, indicating that the coracoid morphology may be a risk factor for fracture and should possibly be determined before surgery.

In contrast, we observed that superior-to-inferior transcoracoid drilling placed the tunnel exit more lateral and resulted in a central to lateral and anterior-to-posterior tunnel direction. Cortical breaks were not observed with this technique may therefore be the preferred approach to reduce cortical breaches and coracoid fractures. Coale et al.<sup>9</sup> have used computed tomography to reconstruct 23 shoulders and have created CC ligament reconstructions using transclavicular–transcoracoid drilling techniques and virtual tendon grafts. Three virtual tunnel techniques were applied: superior clavicular and inferior coracoid landmarks, superior clavicular and superior coracoid landmarks, and central position on the coracoid. The authors concluded that the risk of fracture and coracoid cortical breach was independent of the anatomical parameters used to guide tunnel position.<sup>9</sup> However, central socket drilling minimized fracture and cortical breach risk but was not collinear with the clavicle and could not approximate the clavicle position.<sup>9</sup> The authors suggested that independent tunnel drilling might be a possible solution.<sup>9</sup> The results of this study seem to confirm the conclusions of Coale et al.<sup>9</sup> Surgeons

should consider coracoid tunnel drilling by exposing the superior coracoid process and check inferior guide pin positioning before reaming with the appropriate drill size. With this technique, coracoid shapes and morphology would not influence central tunnel position and possibly would almost always result in a centered tunnel. This would also reduce the risk of coracoid fractures. Olivos-Meza et al.<sup>16</sup> have proposed a freehand drilling technique by placing a smaller 2.4-mm drill guide pin through a predrilled 3.2-mm clavicular tunnel and checking correct placement on both superior and inferior coracoid surface arthroscopically. Unfortunately, clinical data and basic science laboratory data are not available for this technique, and their claim that a freehand drilling technique helps correct guide positioning, accurate central tunnel placement, and reduced complication rates cannot be confirmed. Hoffman et al.<sup>17</sup> have used electromagnetic navigation and have shown that tunnel placement at the desired position was achieved in 15 of the 16 tunnels (94%). In a later study, they compared electromagnetic navigation with a standard minimally invasive method technique, showing that navigation placed tunnels successfully in 99% compared with 84% with standard techniques.<sup>18</sup> Navigation did not require any readjustments, but drill misguidance and cortical breaches were observed in 2 cases (20%) with the standard technique. Custom-made drill guides using 3-dimensional (3D) printing have been developed by Zhang et al.<sup>19</sup> Based on computed tomography images, 3D-printing software was used to create drill guides for transclavicular–transcoracoid tunnel drilling, and they have demonstrated an accuracy of 0.1 mm for 10 measured parameters when assessing tunnel placement in a virtual 3D shoulder model.<sup>19</sup> Central coracoid tunnel placement and projection seems critical to avoid complications. Ferreira et al.<sup>20</sup> have investigated tunnel trajectory and demonstrate that superior center-to-inferior center or superior medial-to-inferior central tunnel orientation reduces the risk of coracoid fracture. Obviously, complication rates for arthroscopic-assisted transclavicular–transcoracoid fixation of acromioclavicular injuries are high and fractures account for 5.8% of complications pooling a variety of surgical techniques but account for 17% of all complications for techniques using buttons and transclavicular–transcoracoid tunnels. These complications can only be reduced by accurate and centered tunnel trajectory.<sup>9,17,18,20</sup>

Theoretically smaller tunnel diameters could reduce the risk of coracoid fractures.<sup>21</sup> Spiegl et al.<sup>22</sup> have shown that a 6-mm tunnel significantly weakens the clavicle when compared to a 2.4-mm tunnel. Whether Spiegl et al.<sup>22</sup> findings can also be applied to the coracoid is unknown. With clavicle tunnel the bending

moment results in flexural stresses, whereas coplanar movement on the coracoid will rather cause stress. Rylander et al.<sup>23</sup> have examined load to failure for 6-mm respectively 4-mm coracoid tunnel diameters and have shown that the smaller tunnel had a load to failure of 296 N compared with 146 N for the 6-mm tunnel. Campbell et al.<sup>24</sup> investigated both concentric and eccentric coracoid tunnel placements using 4.5- and 6-mm tunnels. The authors demonstrated greater load to failure rates for the 6-mm tunnel for both concentric and eccentric drillings but also reported significantly lower higher rates for eccentric tunnels.<sup>24</sup> Recently, different implants<sup>25</sup> allow smaller tunnel coracoid diameter and could potentially reduce the risk of coracoid fractures even if the tunnels were drilled eccentrically.

### Limitations

This study has several limitations. The distance between the posterior margin and inferior tunnel exit could not be obtained due to obstruction of the soft tissues and because the coracoid process could not be removed from the cadaver. However, it could be argued that the base is a virtual imagined construction and not an anatomical feature, as the “base” extends into the superior–anterior part of the glenoid and scapular neck. Therefore, the distance from the apex of the coracoid served as a proxy measure. It is acknowledged that the distance between inferior tunnel position and the coracoid base may be an important variable. However, the main purpose of this study was to establish tunnel eccentricity and the distance from the coracoid base may not be an important denominator of tunnel trajectory. The embalmed cadavers were quite stiff, and arm abduction and exposure of the inferior coracoid surface was challenging. Predrilling was performed with a 2-mm guide pin and a longer 5-mm drill bit was then used for inferior-to-superior tunnel drilling. It cannot entirely be excluded that the longer lever arm has resulted in eccentric drilling. However, the measured distances for both medial and lateral tunnel entry are very similar, making it highly unlikely that eccentric drilling occurred. Arthroscopic drill guides and techniques were not used and the open drilling technique used in this research may not be comparable with in vivo arthroscopic-assisted tunnel placement.

### Conclusions

Both superior-to-inferior and inferior-to-superior tunnel drilling directed the tunnel from a more anterior and medial entry to a posterior-lateral exit. Superior-to-inferior drilling resulted in a more posteriorly angled tunnel. When using a 5-mm reamer, and inferior-to-superior tunnel drilling, cortical breaks were observed at the inferior and medial margin of the tunnel exit.

## References

- Nordin JS, Olsson O, Lunsjö K. Acromioclavicular joint dislocations: Incidence, injury profile, and patient characteristics from a prospective case series. *JSES Int* 2020;4:246-250.
- Chillemi C, Franceschini V, Giudici LD, et al. Epidemiology of isolated acromioclavicular joint dislocation. *Emerg Med Int* 2013;2012:171609.
- Beitzel K, Mazzocca AD, Bak K, et al. ISAKOS upper extremity committee consensus statement on the need for diversification of the Rockwood classification for acromioclavicular joint injuries. *Arthroscopy* 2014;30:271-278.
- Chahla J, Marchetti DC, Moatshe G, et al. Quantitative assessment of the coracoacromial and the coracoclavicular ligaments with 3-dimensional mapping of the coracoid process anatomy: A cadaveric study of surgically relevant structures. *Arthroscopy* 2018;34:1403-1411.
- Joukainen A, Kröger H, Niemitukia L, Mäkelä EA, Väätäinen U. Results of operative and nonoperative treatment of Rockwood types III and V acromioclavicular joint dislocation: A prospective, randomized trial with an 18- to 20-year follow-up. *Orthop J Sports Med* 2014;26:565-574.
- Nolte PC, Lacheta L, Dekker TJ, Elrick BP, Millett PJ. Optimal management of acromioclavicular dislocation: Current perspectives. *Orthop Res Rev* 2020;12:27-44.
- Xue C, Zhang M, Zheng TS, et al. Clavicle and coracoid process drilling technique for truly anatomic coracoclavicular ligament reconstruction. *Injury* 2013;44:1314-1320.
- Koh KH, Shon MS, Choi NH, Lim TK. Anatomic tunnel placement is not feasible by transclavicular-transcoracoid reconstruction: A cadaveric study. *Arthroscopy* 2018;34:2012-2017.
- Coale RM, Hollister SJ, Dines JS, Allen AA, Bedi A. Anatomic considerations of transclavicular-transcoracoid drilling for coracoclavicular ligament reconstruction. *J Shoulder Elbow Surg* 2013;22:137-144.
- Milewski MD, Tompkins M, Giugale JM, Carson EW, Miller MD, Diduch JM. Complications related to anatomic reconstruction of the coracoclavicular ligaments. *Am J Sports Med* 2012;40:1628-1634.
- Martetschläger F, Horan MP, Warth RJ, Millett PJ. Complications after anatomic fixation and reconstruction of the coracoclavicular ligaments. *Am J Sports Med* 2013;41:2896-2903.
- Xin L, Luo J, Chen M, et al. Anatomy and correlation of the coracoid process and coracoclavicular ligament based on three-dimensional computed tomography reconstruction and magnetic resonance imaging. *Med Sci Mon* 2021;27:e930435.
- Gowd AK, Liu JN, Cabarcas BC, et al. Current concepts in the operative management of acromioclavicular dislocations: A systematic review and meta-analysis of operative techniques. *Am J Sports Med* 2019;47:2745-2758.
- Wang C, Meng JH, Zhang YW, Shi MM. Suture button versus Hook plate for acute unstable chronic acromioclavicular joint dislocation: A meta-analysis. *Am J Sports Med* 2020;48:1023-1030.
- Marsalli M, Moran N, Laso JI. Arthroscopic acromioclavicular joint reconstruction with TightRope and FiberTape loop. *Arthrosc Tech* 2018;8:31103-e1108.
- Olivos-Meza, Rodrigues-Argueta ME, Suarez-Ahedo C, et al. Free hand drilling technique to enhance central position of tunnels in arthroscopic acromioclavicular joint fixation using TightRope system. *Arthrosc Tech* 2021;10:e1829-e1837.
- Hoffmann M, Hartel M, Schroeder M, Reinsch O, et al. Electromagnetic navigation provides high accuracy for transcoracoid-transclavicular drilling. *Knee Surg Sports Traumatol Arthrosc* 2014;22:2237-2242.
- Hoffmann M, Schroeder M, Hartel M, et al. Accuracy analysis of a novel electromagnetic navigation procedure versus a standard minimally invasive method for arthroscopically assisted acromioclavicular joint reconstructions. *Arthroscopy* 2014;30:928-935.
- Zhang L, Wen Y, Zhang MY, Zhou X, Fu SJ, Wang GY. Efficacy of transosseous tunnel placement for triple Endobutton plate in acromioclavicular joint reconstruction: A three-dimensional printing guide technology. *Orthop Surg* 2022;14:422-426.
- Ferreira J, Chowanec D, Obopilwe E, Nowak M, Arciero R, Mazzocca A. Biomechanical evaluation of effect of coracoid tunnel placement on load to failure of fixation during repair of acromioclavicular joint dislocations. *Arthroscopy* 2012;28:1230-1236.
- Berthold DP, Muench L, Dyrna F, et al. Current concepts in acromioclavicular joint (AC) instability—a proposed treatment algorithm for acute and chronic AC-joint surgery. *BMC Musculoskelet Disord* 2022;23:1078.
- Spiegel UJ, Smith SD, Euler SA, Dornan GJ, Millett PJ, Wijdicks CA. Biomechanical consequences of coracoclavicular reconstruction techniques on clavicle strength. *Am J Sports Med* 2014;42:1724-1730.
- Rylander LS, Baldini T, Mitchell JJ, Messina M, Ellis IA, McCarty EC. Coracoclavicular ligament reconstruction: Coracoid tunnel diameter correlates with failure risk. *Orthopedics* 2014;37:e531-e535.
- Campbell ST, Heckmann ND, Shin SJ, et al. Biomechanical evaluation of coracoid tunnel size and location for coracoclavicular ligament reconstruction. *Arthroscopy* 2015;31:825-830.
- Kumar Y, Rahul P, Kambhampati S, Vanchit S. Arthroscopic reconstruction of acute acromioclavicular joint disruption using dog-bone button construct: A prospective study. *J Arthrosc Joint Surg* 2020;7:151-156.